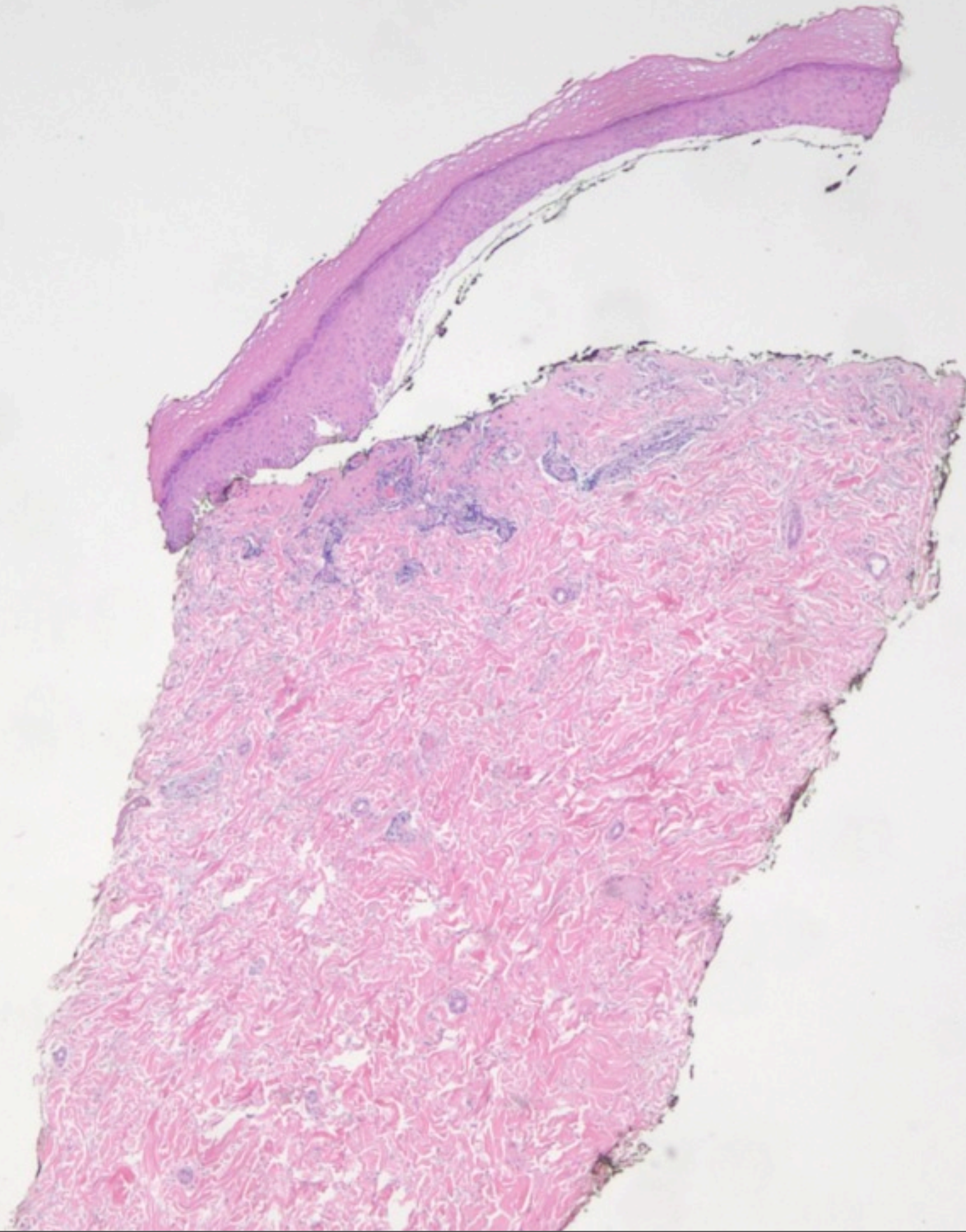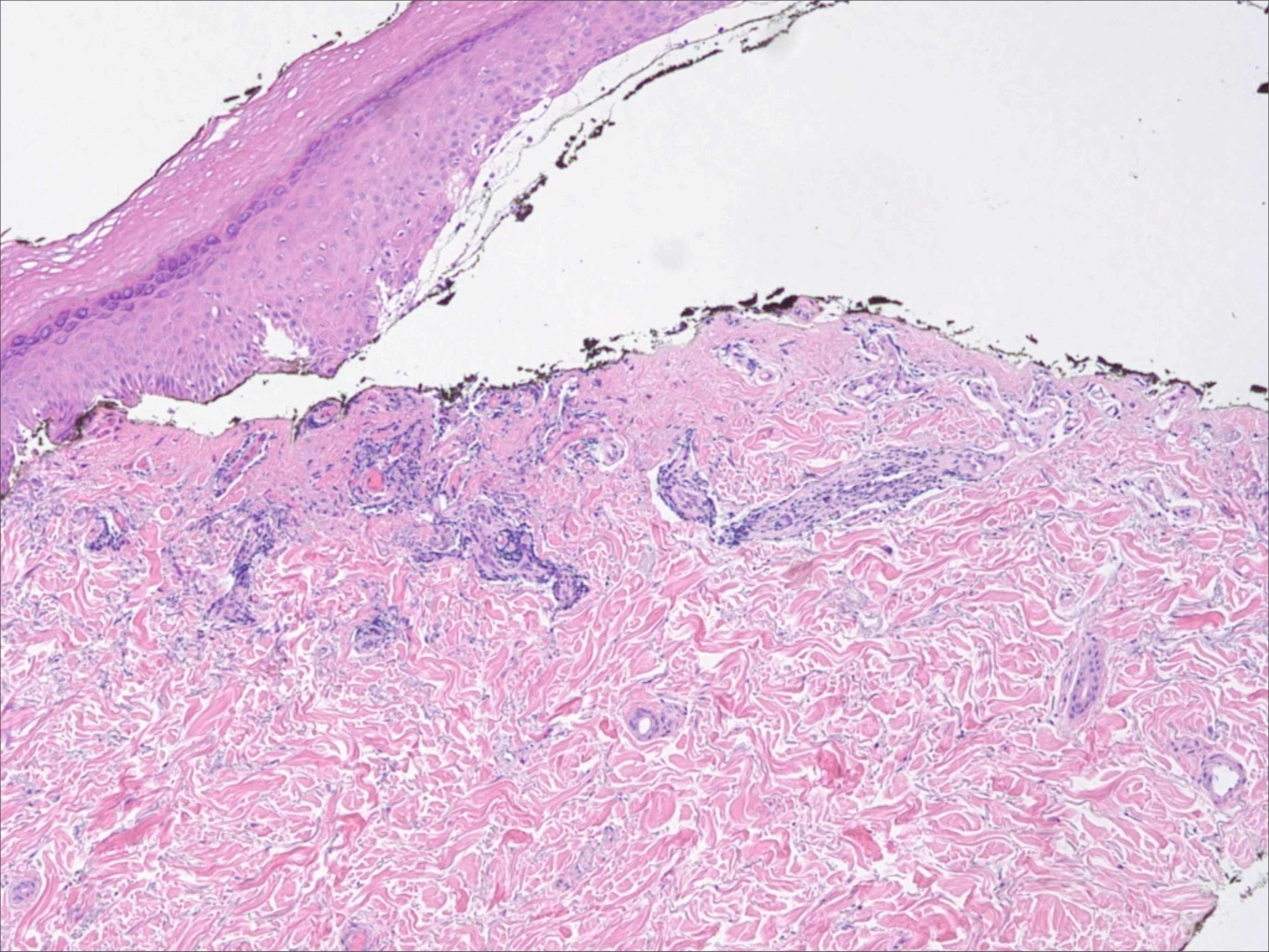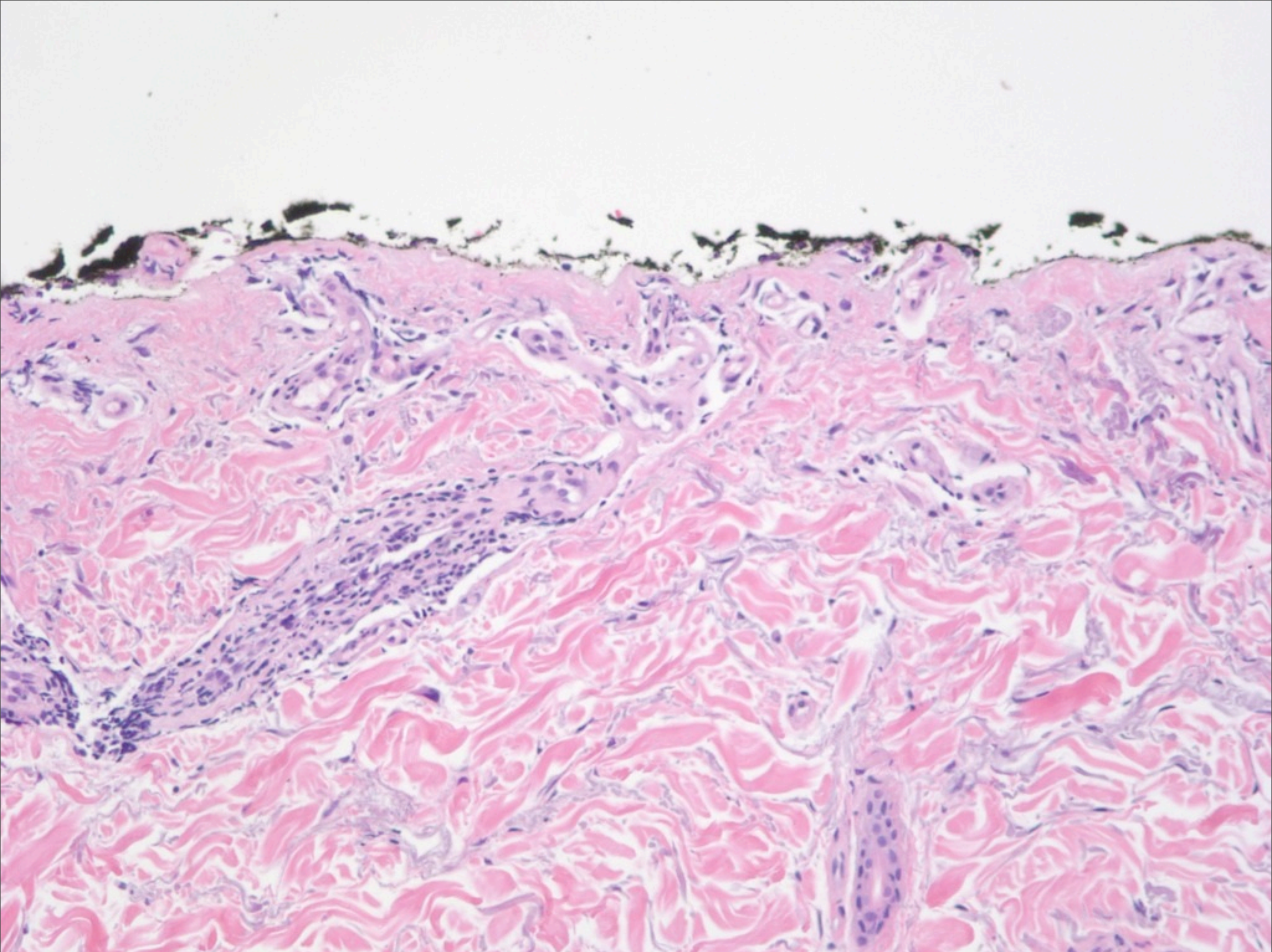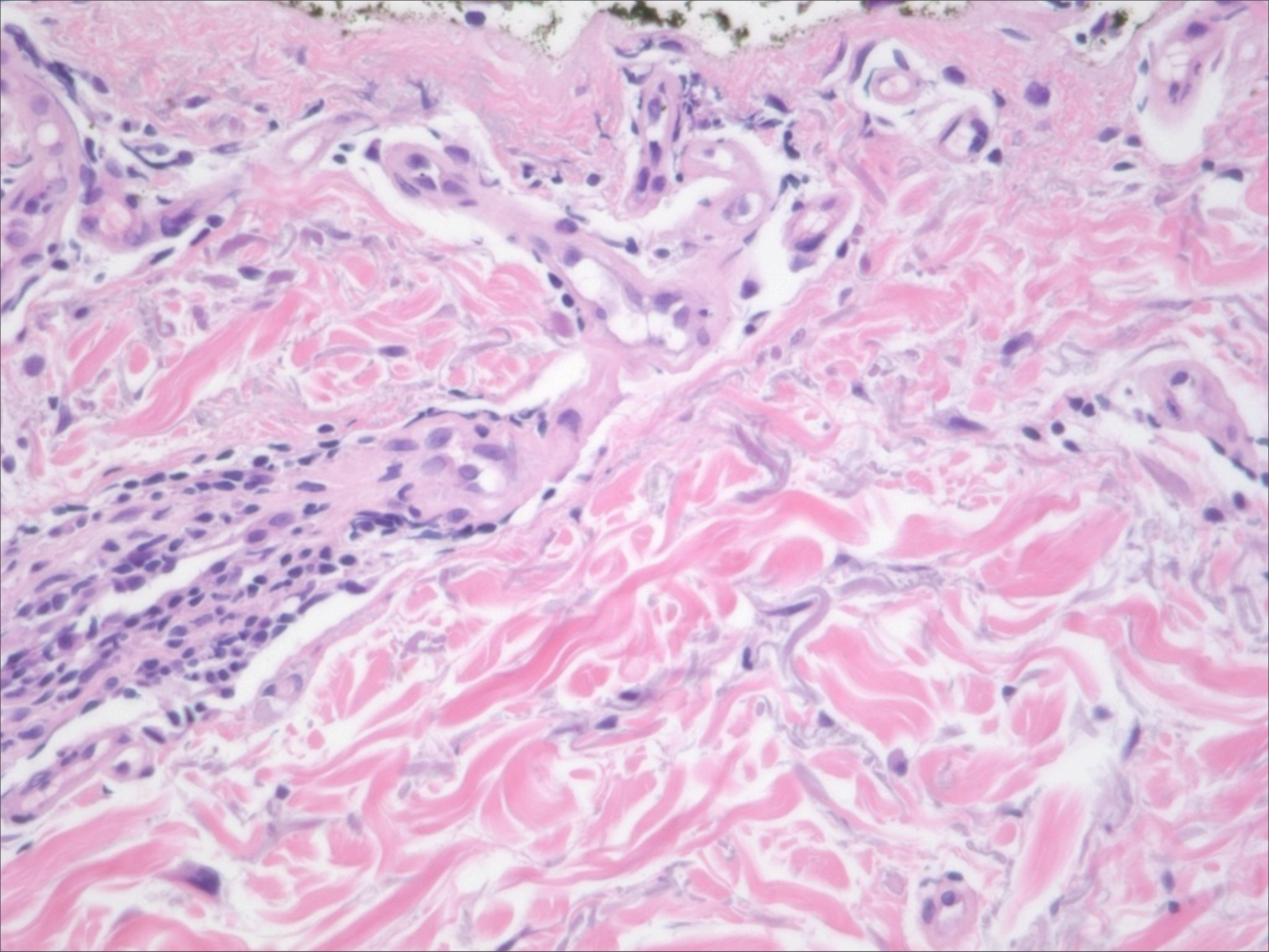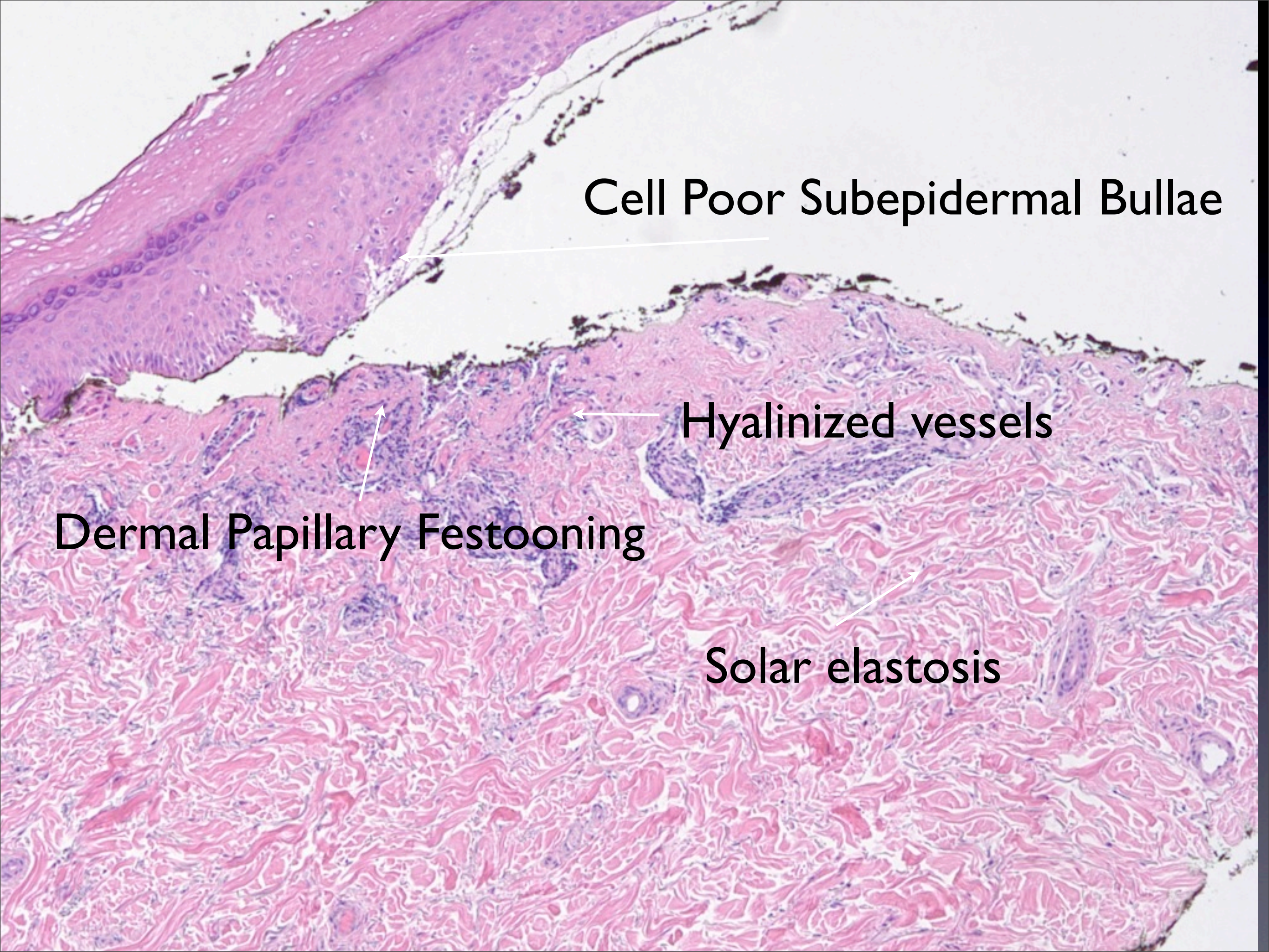


Porphyria Cutanea Tarda



Cell Poor Subepidermal Bullae

Hyalinized vessels

Dermal Papillary Festooning

Solar elastosis